

Article

# Size reduction and improvement of ano-genital warts plate through the application of MIX557-Oleum Hyperici and Neem oil before surgical removal. Preliminary results

Claudia Menconi<sup>1</sup>, Laura Del Bono<sup>2</sup>, Alessandro Sturiale<sup>1</sup>, Bernardina Fabiani<sup>1</sup>, Dowais Raad<sup>1</sup>, Riccardo Morganti<sup>3</sup>, Gabriele Naldini<sup>1</sup>.

<sup>1</sup>Proctological and Perineal Surgical Unit, Department of General Surgery, Cisanello University Hospital, Pisa, Italy

<sup>2</sup>Infectious diseases Unit, Department of Medical Specialties, Cisanello University Hospital, Pisa Italy

<sup>3</sup>Section of Statistics, University Hospital of Pisa

\*Correspondence: Claudia Menconi, Proctological and Perineal Surgical Unit, Cisanello University Hospital, Via Paradisa 2, Pisa, Italy; Tel: 0039050997411; E-mail: claudia.menconi14@gmail.com

Received: 25 February 2019; Accepted: 15 March 2019; Published: 31 March 2019

**Abstract.** *Background:* Ano-genital warts are a common manifestation of Human Papilloma virus infection (HPV), which is one of the most frequent sexually transmitted diseases. Nowadays the only chance to treat ano-genital warts is based on two different approaches: topical medication or surgical excision. In some patients the local excision of large zones of perineal condylomatosis leads to bothering perianal scars. *Objectives:* To evaluate the effect of MIX557-Oleum Hyperici and Neem oil on ano-genital warts before and after surgical excision; before, to reduce the size of warts, and after, to evaluate the wound healing and percentage rate of wart recurrences. *Methods* MIX557-Oleum Hyperici and Neem oil was used in three patients eligible for conventional surgery. The application of MIX557 was twice daily for 6 weeks and the dimension and size were measured before and after the treatment. *Results:* In all cases there was a significant regression of the lesions size and a change of shape of the warts plate into "smaller islands". The reduction of the warts dimension allowed a less invasive surgery with smaller wounds and a one-step excision. *Conclusion:* MIX557-Oleum Hyperici and Neem oil showed a clinical effect probably based on an immunomodulatory action whose impact on HPV-related lesions deserves investigation. In fact,

further studies are needed to analyze the correlation between the clinical response and HPV genotype, or the state of immune system in patients with or without HIV infection.

**Keywords:** ano-genital warts, HPV, oleum Hyperici Neem oil, AIN, CIN.

---

## Introduction

Ano-genital warts are a common manifestation of Human Papillomavirus (HPV) infection, which is one of the most frequent sexually transmitted diseases. Approximately 30,000,000 people are diagnosed with ano-genital warts each year, and around 640,000 of them have an HPV-related neoplasm in different sites, such as the cervix, vagina, vulva, anus, penis or the oropharynx. Moreover, HPV-related cancer represents 4.5% of all cancers worldwide, and is the second most common cause of infection-related cancer.<sup>1-3</sup>

Nowadays the only chance to treat ano-genital warts is based on few approaches: local (topical) medication, cryotherapy and surgical excision with histological studies, with the last being the best option. The first two approaches are generally indicated in the case of small lesions, with an already known histology and viral genotype. Surgery is otherwise a radical treatment; it can be considered a first-line therapy or a second-line treatment following local control of the lesions by drugs. Tissue histopathological analysis and HPV-genotype identification together with the immunity state of the patient, allow subsequent patient stratification by risk class.

In our multidisciplinary centre for the treatment of sexually transmitted diseases, more than 50% of patients are affected by a surgically treated ano-genital condylomatosis (a mean of 40 patients treated surgically per year with an increasing trend). The main treatment of this condition is the surgical excision which results in a perianal wound. We generally use the application of MIX557-Oleum Hyperici and Neem oil to promote wound healing, thus enhancing the growth of the tissue and leading to a reduction of the healing time and a faster recovery. However, in some patients the widespread of perianal condylomatosis does not allow a single-step surgical excision, so sometimes - although rarely - we perform a two-stage approach: a surgical excision of one perianal side, and excising the lesions of the other side few weeks later. In these cases, after the application of MIX557-Oleum Hyperici and Neem oil on the wound in the side operated we observed a significant clinical reduction of the residual contralateral warts in contact with these medications of wound healing, in terms of size and local inflammation. This had led to a second less invasive surgical procedure on the side left affected by warts. From this clinical observation we have hypothesized the potential benefits of using MIX557-Oleum Hyperici and Neem oil on the skin and mucous membranes affected by massive condylomatosis, manifested in a better immune response against the HPV with a significant reduction in the size of its lesions.

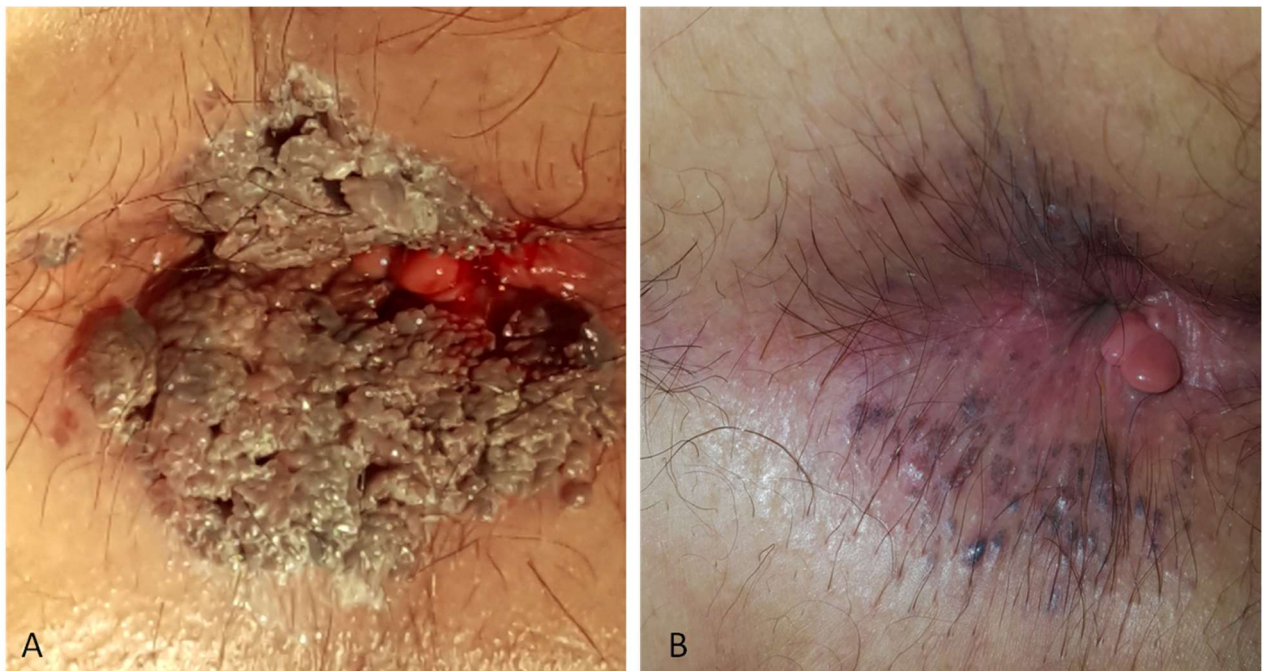
## Materials and Method

### Results

The multidisciplinary team, dedicated to the diagnosis and treatment of sexually transmitted diseases, decided to treat three patients affected by massive perianal condylomatosis with local application of MIX557-Oleum Hyperici and Neem oil, as a neo-adjuvant therapy.

Two patients were HIV positive and belonged to the high-risk class (to develop an HPV-related dysplasia), while one patient was HIV negative and belonged to the moderate risk class. The application of MIX557 was twice daily for 6 weeks, and it revealed a significant clinical reduction of the size in all cases. In one case there was an almost complete regression (**Figure 1**).

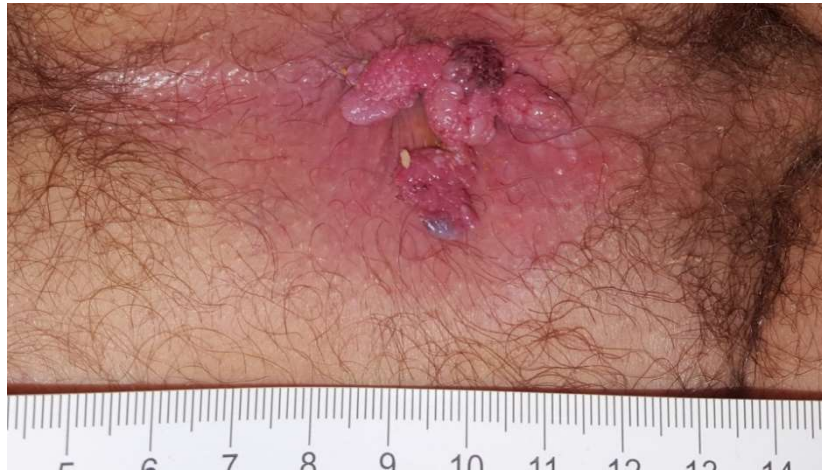**Figure 1 - Patient n 1. Perianal condilomatosis before (A) and after (B) the treatment with MIX557-Oleum Hiperici and Neem oil**



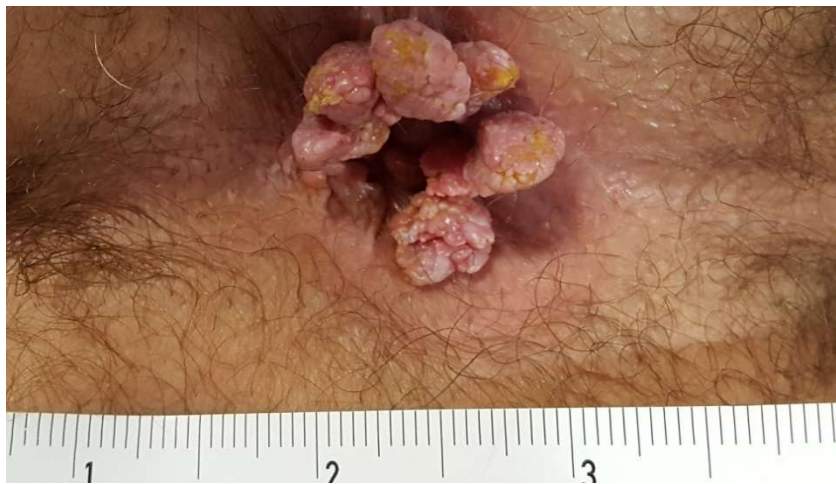**Figure 1**

The other two patients had a reduction of more 40% and 50% respectively of the condylomatosis plates' size (Figure 2 the patients with the reduction of the 40% and figure 3 of the 50%).

**Figure 2 - Patient n. 2 . Perianal condilomatosis before (A) and after (B) the treatment with MIX557-Oleum Hiperici and Neem oil.**

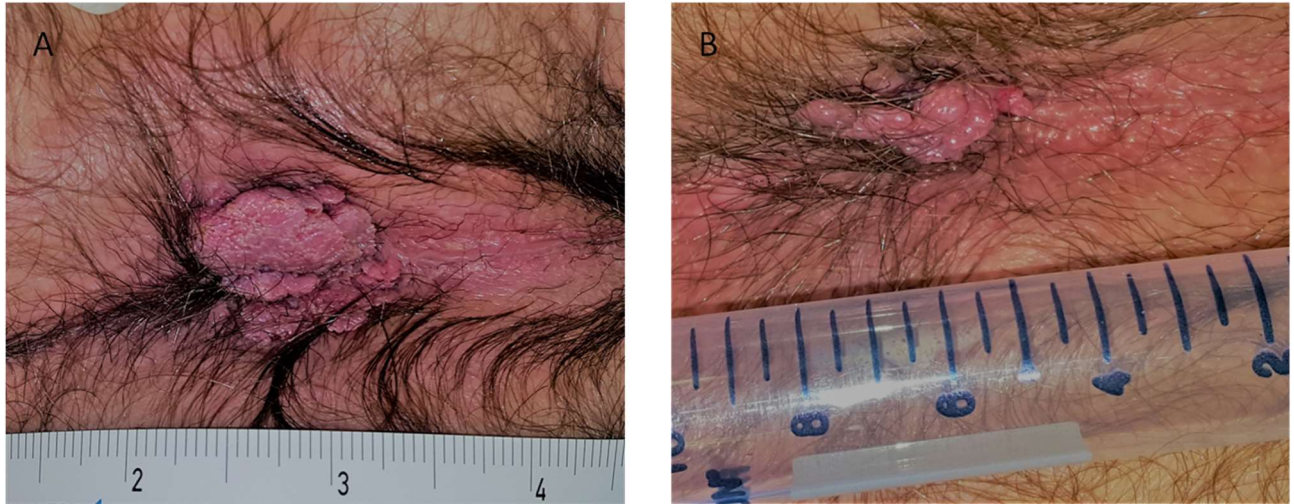


**Figure 2 A**



**Figure 2 B**

**Figure 3 - Patient n 3. Perianal condilomatosis before (A) and after (B) the treatment with MIX557-Oleum Hiperici and Neem oil**



After the application of the MIX557 oil the shape and size of the warts plate have changed to become like a “pedunculated islands of tissue”, which can be surgically removed leaving smaller wounds. The measurements of the size before and after treatment were calculated by the Statistical Centre for the clinical trials of our hospital. All the patients (table 1) after medical treatment underwent surgery with smaller lesions, and consequent smaller perianal wounds and scars. The histological analysis and relative genotyping of the specimens confirmed HPV lesions as described in **Table 1**.

**Table 1 - Size of warts plate pre and post treatment with MIX557 (1 Primary Wound Dressing), Histological findings of post operative specimens**

	Age	Gender	HIV status	Size Area(cm <sup>2</sup> ) pre/post treatment	Post-op specimens, HPV genotypes
<b>Patient 1</b>	63	F	neg	2.0 /0.02	Little warts, P16 negative HPV negative
<b>Patient 2</b>	54	M	pos	0.785/0.371	Warts ASCUS, P16 positive, HPV types 11-16-52-58
<b>Patient 3</b>	41	M	pos	1.5/0.785	Warts, P16 negative HPV 11

The follow-up was scheduled according to the risk class, and all of them declared mild local pain (mean pain VAS scale was 3). At the last follow-up, six months after the beginning of local treatment and three months after surgery, there was no more ano-genital lesion and the wounds were completely healed without shrinking scars.

## Discussion

Ano-genital warts are common lesions in patients with HPV infection and their likelihood to evolve into an anal cancer requires a particular attention by the coloproctologist with a periodical follow-up. Because of the multiple local manifestations in different sites and organs, the development of dedicated centre for diagnosis and treatment allows to perform a complete evaluation and to propose dedicated pathways.

An important issue which goes parallel to the oncologic matter is the impact on patients' quality of life due to multiple surgical treatments for ano-genital warts, which are often recurrent. In fact, most frequent post-operative symptoms after several surgical procedures are passive anal incontinence with soiling and inelastic or stenotic anus. The latter may determine an outlet obstruction and the need to constantly use stool softeners or even enemas. Another possible consequence is the effect on anal intercourse, which may become painful, influencing the quality of life and sexual health.

The rationale of pre and post-surgical treatment of ano-genital warts through the application of MIX557-Oleum Hyperici and Neem oil (trade mark 1 Primary Wound Dressing) comes from clinical observation and published literature. Indeed, the efficacy of this product as a co-adjuvant of the healing process has been already reported<sup>4</sup> and one of the main applications is for complex wounds. Perianal wounds after surgery may be considered as complex wounds<sup>5-12</sup> because they are often wide, with chronic infection due to the constant contact with stool residue, and also because the healing process is influenced by the general condition of the patient, such as concomitant multiple infectious diseases or immunosuppression state.

Moreover, an interesting point is that HPV has a similar structure of the Orf virus which is a prototype of the Parapoxvirus genus. It is the principal cause of the pustular dermatitis called Ecthyma Contagiosum in sheep. Orf virus penetrates through the skin lesions and replicates in epidermal cells. Galligioni *et al.* evaluated the effect of application of MIX557-Oleum Hyperici and Neem oil on the skin and the mucosal lesions of lambs. To explain the clinical results the authors hypothesized the ability of MIX557-Oleum Hyperici and Neem oil to inhibit the Vascular Endothelial Growth Factor (VEGF-E) showing an anti-carcinogenic activity. Currently, the most likely hypothesis is that MIX557-Oleum Hyperici and Neem oil with its healing and immunomodulatory properties, inhibits the virus injurious activity and its cellular transmission too.<sup>6</sup> This background associated with our clinical observation of warts plate regression has led us to develop the application of this product in a different field.

The features of MIX557-Oleum Hyperici and Neem oil are really promising. For promoting complex wound healing<sup>7</sup> it may be applied on skin lesions or mucosa without any type of side effects such as burning or pain. Conversely, these are usually typical symptoms after the application of immunomodulatory ointments such as Imiquimod, so it cannot be even used for

mucosal lesions.<sup>8</sup> Moreover, in case of application of conventional immunomodulatory medications, removal of residual warts should be postponed until complete recovery of drug-induced erythema or perianal pustules is obtained. Therefore, MIX557-Oleum Hyperici and Neem oil may be used preoperatively to downstage the lesions, and postoperatively to promote wound healing, thus obtaining a twofold advantage. The lack of mucosal or perianal skin wounds due to the product allows the surgeon to decide the right moment for local debulking of the disease. Furthermore, regarding HPV-related cancer it can be considered as an adjuvant therapy for the treatment of AIN<sup>9</sup> or CIN lesions exploiting its immunomodulatory effect.

Regarding the patient with a near total regression of condylomatosis plate (**table 1 case 1**), some authors described the spontaneous regression of HPV lesions like CIN III<sup>10</sup> or flat condylomata of the cervix<sup>11</sup> but nobody described a spontaneous regression of large plate of ano-genital warts.

Although this report is only a clinical observation on a very small number of patients, it opens doors for new managing scenarios of HPV infection and its related manifestations whose incidence has a great economic, social and public health impact.

Hence, this preliminary experience showed an important role of MIX557-Oleum Hyperici and Neem oil in the neoadjuvant treatment of ano-genital warts. Further studies are needed to analyze the correlation between the clinical response and HPV genotype, in patients with different states of immunity, particularly with or without HIV infection. A multicenter study approved by the Ethical Committee of our Hospital (protocol nr. 6610) is starting with 100 patients to be recruited and will last 36 months: the objective of the study is to prove the possible immunomodulation action of MIX557-Oleum Hyperici and Neem oil against HPV related lesions.

Funding: no funding will be received to perform the study.

Conflict of interest: none.

## References

1. de Martel C, Plummer M, Vignat J, Franceschi S. Worldwide burden of cancer attributable to HPV by site, country and HPV type. *Int J Cancer* 2017 Aug 15;141(4):664-70.
2. Dillner J, Kjaer SK, Wheeler CM, Sigurdsson K, Iversen OE, Hernandez-Avila M, et al. Four year efficacy of prophylactic human papillomavirus quadrivalent vaccine against low grade cervical, vulvar, and vaginal intraepithelial neoplasia and anogenital warts: randomised controlled trial. *BMJ* 2010 Jul 20;341:c3493.
3. Plummer M, de Martel C, Vignat J, Ferlay J, Bray F, Franceschi S. Global burden of cancers attributable to infections in 2012: a synthetic analysis. *Lancet Glob Health* 2016 Sep;4(9):e609-e616.
4. Mainetti S, Carnevali F. An experience with paediatric burn wounds treated with a plant-derived wound therapeutic. *J Wound Care* 2013 Dec;22(12):681-5, 688.

5. Ferreira MC, Tuma P, Jr., Carvalho VF, Kamamoto F. Complex wounds. *Clinics (Sao Paulo)* 2006 Dec;61(6):571-8.
6. V.Galligioni, F.Carnevali, S.A.VanderEsch, . Attività Antivirale nei confronti di ORF virus di un medicamento (MIX 557) a base di Azadiracta Indica (albero del Neem) e Hypericum perforatum. Published I QuaderniZooBioDi N. 3/2010;96-102. 2017.
7. Carnevali F,, .Castrignanò F, VanderEsch SA. Early appearance Sacral Pressure Ulcer in Elderly Patient treated with Innovative Topical Remedy Mix 557 having Healing Properties: A Case Report. Presented at EWMA, 2007 Glasgow. 2017.
8. Werner RN, Westfechtel L, Dressler C, Nast A. Anogenital warts and other HPV-associated anogenital lesions in the HIV-positive patient: a systematic review and meta-analysis of the efficacy and safety of interventions assessed in controlled clinical trials. *Sex Transm Infect* 2017 Dec; 93 (8): 543-550.
9. Roberts JR, Siekas LL, Kaz AM. Anal intraepithelial neoplasia: A review of diagnosis and management. *World J GastrointestOncol* 2017 Feb 15;9(2):50-61.
10. Motamed M, Bohmer G, Neumann HH, von Wasielewski R. CIN III lesions and regression: retrospective analysis of 635 cases. *BioMed Central Infectious Disease* 2015 15:541:1-9
11. Courtial I, Bremond A, Akin D. Spontaneous regression of flat condylomata of the cervix. *J GynecolobstetBiolReprodu (Paris)* 1991;20(4):527-31
12. Del Missier A, La Torre F, Toma E. Treatment of Peristomal granulomatosis with Neem and Red Hypericum Oil application: Case studies. *Clin Ter.*2019 Mar-Apr;170(2):e86-92