

Article

Evaluation of the outcomes of staged repair for primary bilateral cleft lip with or without cleft palate in infants: a prospective case series

Omar Moustafa Fawzy¹, Ahmed Mohamed Khairi Gabr¹, Saber Mohamed Waheeb¹,
Hossam Yehia El-Kafrawy¹, Mohamed Abd El-Ghafour¹, Mamdouh Aboulhassan¹

¹Paediatric Surgery, Faculty of Medicine, Alexandria University

*Correspondence: Omar Moustafa Fawzy, Assistant lecturer of Paediatric Surgery, Faculty of Medicine, Alexandria University; E-Mail:omar.m.fawzi@gmail.com

Abstract. *Background:* Bilateral cleft lip surgery is challenging for the paediatric plastic surgeon. Different surgical techniques are described for bilateral cleft lip repair either in on stage or multiple stages. The main limitation reported for the one stage technique is the excessive tension encountered during the repair while the main limitation of staged techniques overall was the ability to achieve good upper lip symmetry after the final repair. In our study, we evaluated the symmetry of bilateral clefts after performing a staged repair that consisted of muscle mobilisation at the first stage followed by the full repair at the second stage. *Methods:* We performed staged repair to 20 patients having bilateral cleft lip after the nasoalveolar molding unless the patient presented to us beyond the age of 3 months. The selection criteria were: 1) Patients that had a severely projected premaxilla. 2) rotated premaxilla 3) vertical height of the prolabium less than 6 mm 4) asymmetric bilateral clefts. 5) failed nasoalveolar molding 6) patients that did not undergo nasoalveolar molding. We excluded patients with facial clefts. We performed the first stage at the age of 3 months by muscle mobilisation from the premaxilla and without any muscle dissection from the skin or mucosa and then we performed the second stage at the age of 18 months. We performed frontal photometric analysis to our patients after the second stage repair. *Results:* Only one patient with rotated premaxilla in our study showed partial disruption of the wound on one side after the first stage and had redo of the first stage 3 months later, otherwise no complications were encountered. All patients showed good symmetry of the upper lip by photometrical analysis. *Conclusion:* The staged repair of the bilateral cleft is safe and leads to good symmetry of the upper lip. Further prospective studies with larger samples are needed.

Keywords: cleft lip, bilateral, staged repair, symmetry, photometrical analysis

Introduction

Cleft lip is a very challenging congenital anomaly to be managed with for paediatric plastic surgeons. The incidence of clefting varies among different races. Cleft lip could be unilateral or bilateral and the presence of cleft lip either unilateral or bilateral can be associated with cleft palate or can be isolated.(1)

Bilateral cleft lip surgery is very challenging for the experienced paediatric plastic surgeon.(2) The proper management of bilateral cleft patients should always be based on multidisciplinary approaches. The anatomical reconstruction of the oral and nasolabial regions should allow the improvement of the function and the aesthetics with acceptable symmetry. The recent surgical approaches should thus provide an anatomical basis that allows the facial structures to grow symmetrically.(3) Different surgical techniques are described for bilateral cleft lip repair. The main principle of all of these techniques is the precise as well as proper dissection of the orbicularis oris pathological muscle insertions whether in a one stage or staged approach and their reinsertion correctly to reconstruct the normal nasolabial anatomy.(4, 5)

Some surgeons support the one-stage bilateral cleft lip repair at 3 months of age especially for patients having complete and symmetric bilateral cleft lip. The two-stage lip repair is selected by many paediatric plastic surgeons for patients having asymmetric bilateral clefts, an "extremely small prolabium (6 mm in vertical height or less) and a severely projected or rotated premaxilla. The staged approach can consist of primary bilateral lip adhesion followed by the definitive lip repair, primary bilateral muscle mobilisation and then definitive repair at the following stage or complete repair side by side. The main limitation encountered by surgeons who perform a one stage repair is the excessive tension on the muscles especially in patients having a displaced premaxilla or a small prolabium. As regards simple lip adhesion, it could be insufficient in many cases especially those with displaced premaxilla because the muscles were not mobilised at all. Many surgeons who perform a side by side full repair for bilateral clefts report limitations to achieve an acceptable degree of lip symmetry.(6-13)

In our study, we aimed to evaluate the symmetry of bilateral clefts after performing a staged repair that consisted of muscle mobilisation at the first stage followed by the full repair at the second stage.

Patients and Methods

We carried a prospective case series on 20 patients from February 2021 to June 2022 in the Plastic Surgery Department of Cairo University and in the Plastic surgery department of Alexandria University. The study was carried out

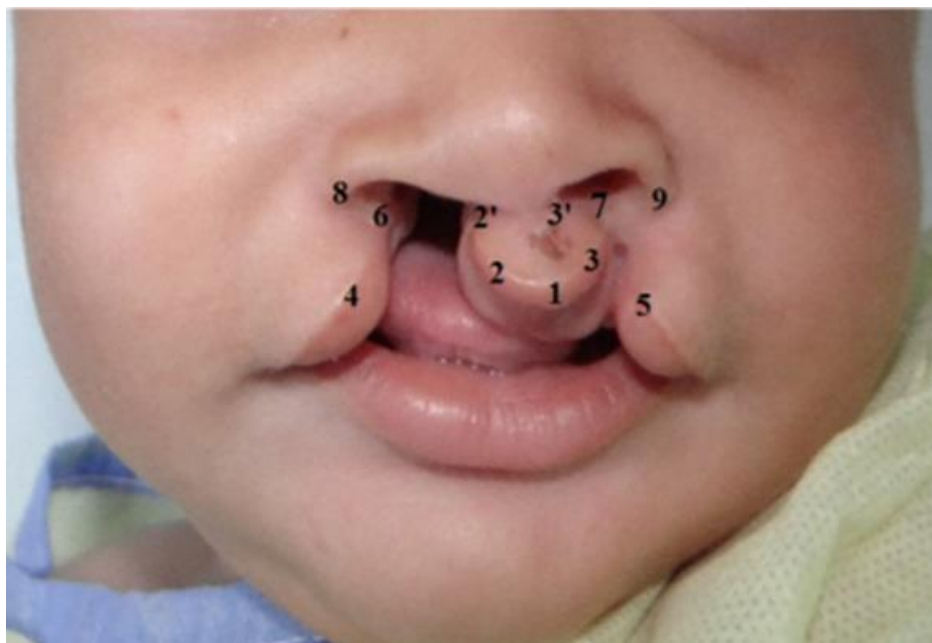according to ethical standards of scientific research and it was approved by the Ethics Committee of faculty of medicine in Alexandria university and Cairo university. We obtained an informed consent for every patient. Nasoalveolar molding was performed before the first stage but we did not perform it for patients who were 3 months old or older than that. The inclusion criteria were: 1) Patients that had a severely projected premaxilla. 2) rotated premaxilla 3) vertical height of the prolabium less than 6 mm 4) asymmetric bilateral cleft lip 5) failed nasoalveolar molding 6) patients that did not undergo nasoalveolar molding. We excluded patients with facial clefts from our study.

Surgical technique

First stage (at the age of 3 months)

We performed the first at the age of 3 months. Point 1 represented the midline of the prolabium at the level of the white roll. Points 2 and 3 were marked at the level of the cupid's bow peaks on the right side and left side respectively. Points 2' and 3' represented the columellar base at both sides. Points 4 and 5 were marked on Nordhoof point(14) on both sides ; We aimed at approximating points 4 and 5 to points 2 and 3 respectively at the end of the first stage. Points 8 and 9 marked the alar base on both sides.

Figure (1): Shows the marking landmarks of the first stage



We infiltrated the lip with local anesthetic at points 2,3,4 and 5 (2% xylocaine with 1/200,000 adrenaline).

We incised on both sides of the prolabium from point 2' to point 2 on the right side and from point 3' to point 3 on the left side.

We performed 2 other curved incisions on the lateral cleft sides from point 8 to point 6 and till point 4 (14) on the right side and from point 9 to point 7 till point 5 on the left side.(14)

We released the muscles attached to the lateral part of the maxilla and alar base by supra periosteal dissection.

We did not dissect the muscles from the skin nor the mucosa at this stage.

Following this dissection, the mucosal layer and the muscles on each side were sutured to the subcutaneous layer of the prolabium .We sutured finally the skin of the lateral lip segments to each side of the prolabium. We used 4/0 vicryl for the muscles and mucosa and 5/0 vicryl for the skin.

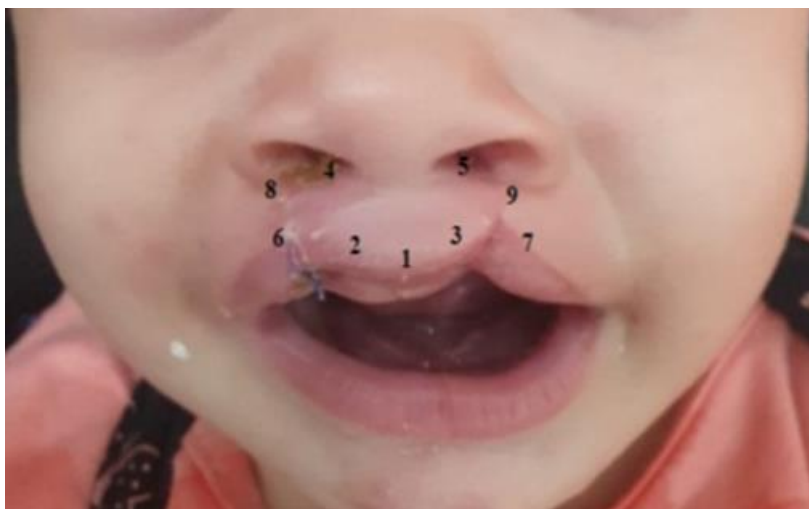In patients having cleft palate, we closed the anterior palate at this stage in one layer by getting a vomerine flap on the medial side and a mucoperiosteal flap on the lateral side then suturing them to each other by 5/0 vicryl.

If the patient had cleft soft palate as well, we closed it at the age of 10 months by Furlow Z plasty with a buccinator flap.

As regards the patients that had complete or incomplete cleft on one side and a microform anomaly on the other side, a simple nasolabial adhesion was then performed on the microform side without muscular dissection because we didn't need it for this side in order to attach the muscles of the lateral lip segment to the prolabium without tension but the other side with complete or incomplete cleft was managed as we described before.

Second stage (at the age of 18 months)

Figure (2): the landmarks for the second stage.



Point 1 represented the midline of cupid bow. We marked the expected high point of Cupid bow by 2 and 3 on the right and left side respectively by measuring 2 mm from point 1 on each side to have a total width of 4 to 5 mm. Points 4 and 5 represented the lateral base of the columella on each side. A line was drawn from point 2 to 4 and 3 to 5 respectively and the line tapered slightly centrally on the upper side.

Points 6 and 7 represented Noordhoff point (14) on both sides. Points 8 and 9 marked the base of the ala on each side.

We injected the lip with local anesthetic at points 2,3,6 and 7 (2% xylocaine with 1/200,000 adrenaline).

We performed the lateral advancement flap incision from points 8 to 6 and 9 to 7 on each side.

We dissected the muscles away from the maxilla in a supraperiosteal plane. We placed our finger on the infraorbital foramen in order to protect the orbit and the infraorbital nerve.

We dissected further the orbicularis oris muscle in the lateral lip segment from the skin and alar base for 5 mm. We dissected the muscle also meticulously from the mucosa for 4 mm.

We incised the prolabium from point 2 to 4 and 3 to 5 on each side.

We raised the prolabial flap with the minimal amount possible of subcutaneous tissue and by taking into account the neophiltrum's vascularity.

The floor of nose was closed with 4-0 absorbable suture and the operating surgeon preserved as much mucosa as possible to prevent any nostril stenosis. The closure would then lead to acceptable symmetry in width and a natural position for the ala.

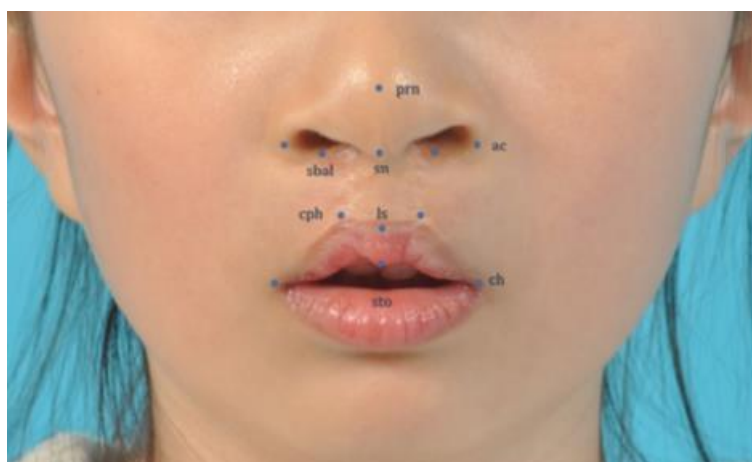We closed the muscles and mucosa with 4-0 vicryl sutures. We closed then the overlying skin by 6-0 monocryl interrupted sutures.

We adjusted the prolabial flap before skin closure after assessment of the vascularity of the flap.

Outcomes Assessment

We performed frontal view photometrical analysis using a special computer software in order to assess the upper lip symmetry (sbal-cph distance), the horizontal lip length symmetry (sto-ch distance), the cupid's bow symmetry (ch-cph-is angle) and the alar symmetry (ac-sn distance) as shown in the Figure 3.(10, 15, 16)

Figure (3): Shows the points we used for frontal photometrical analysis.(10)



Statistical analysis of the data

We analysed data using IBM SPSS software package version 20.0. (Armonk, NY: IBM Corp). We used the Kolmogorov-Smirnov test to verify the normality of distribution. We described quantitative data using range (minimum and maximum), mean, standard deviation and median. We judged the significance of the obtained results at the 5% level.

We used the student t-test for normally distributed quantitative variables in order to compare between the right and left side measurements for every patient.

Results

In our study, 5 patients had positive familial history of cleft lip(25%)

We performed nasoalveolar molding to all the patients in our study except 5 patients (25%) that were 3 months old or older at the time of the study.

We performed staged repair to all patients. Among our patients,10 had asymmetric cleft lip (50%) and 7 had complete bilateral symmetric cleft lip associated with protruded premaxilla (35%) and 4 patients among them did not undergo nasoalveolar molding. The remaining 3 patients with protruded premaxilla had a prolabium less than 6 mm in height and based on that they were included in our study. We had 3 patients with rotated premaxilla and 1 of them did not undergo nasoalveolar molding(15%).

The patient that had rotated premaxilla and no presurgical nasoalveolar molding had partial disruption of the wound following the first stage on the right side and required then redo of the first stage on this side after 3 months .We performed the second stage for this patient at the age of 2 years (3 surgeries for the

lip). None of the other patients had acute complications in the form of hematoma, wound dehiscence, infection or disruption of the wound.

We found no statistical significance between the right and left measurements as regards the upper lip symmetry, the horizontal lip length, the cupid bow's symmetry and the alar symmetry after the frontal photometric analysis.

Table (1): Comparison between Right and Left according to anthropometry (photogrammetry)

	Measurements	Left/Right Ratio	p
Upper lip symmetry	sbal-cph distance	1.017	0.915
Horizontal lip length	sto-ch distance	1.008	0.752
Cupid's bow symmetry	ch-cph-ls angle	1.014	0.610
Alar symmetry	ac-sn distance	1.0	0.836

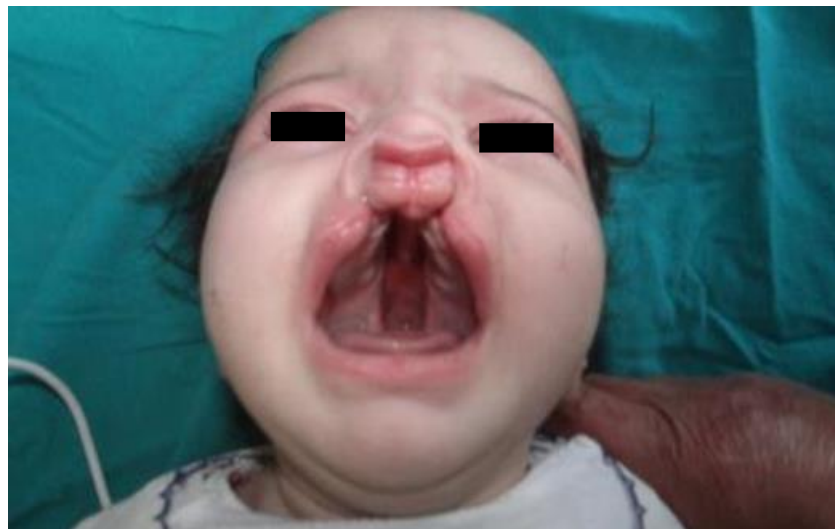

Figure (4): first patient before the first stage.

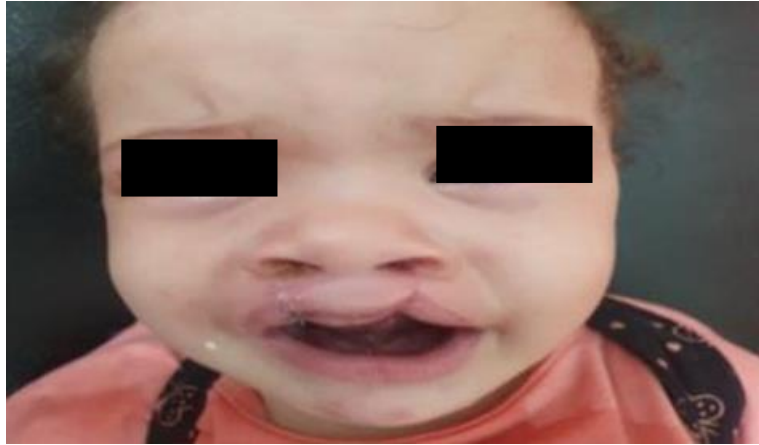

Figure (5): First patient following the first stage.

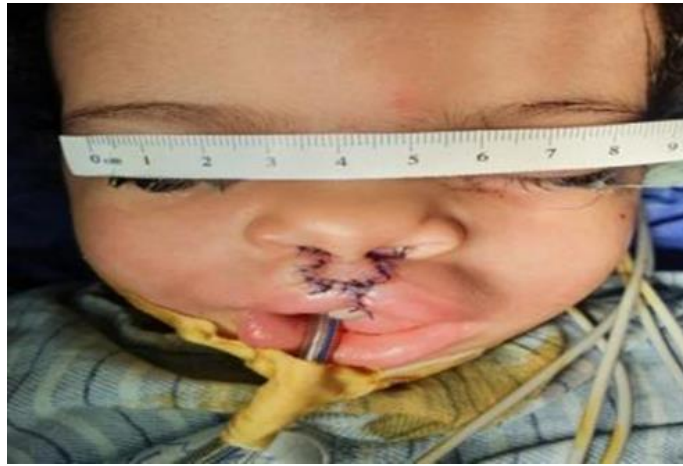

Figure (6): the first patient following the second stage.

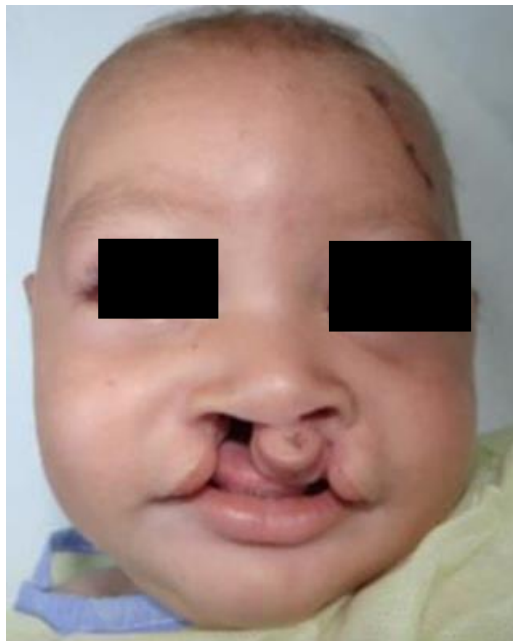

Figure (7): the second patient before the first stage.

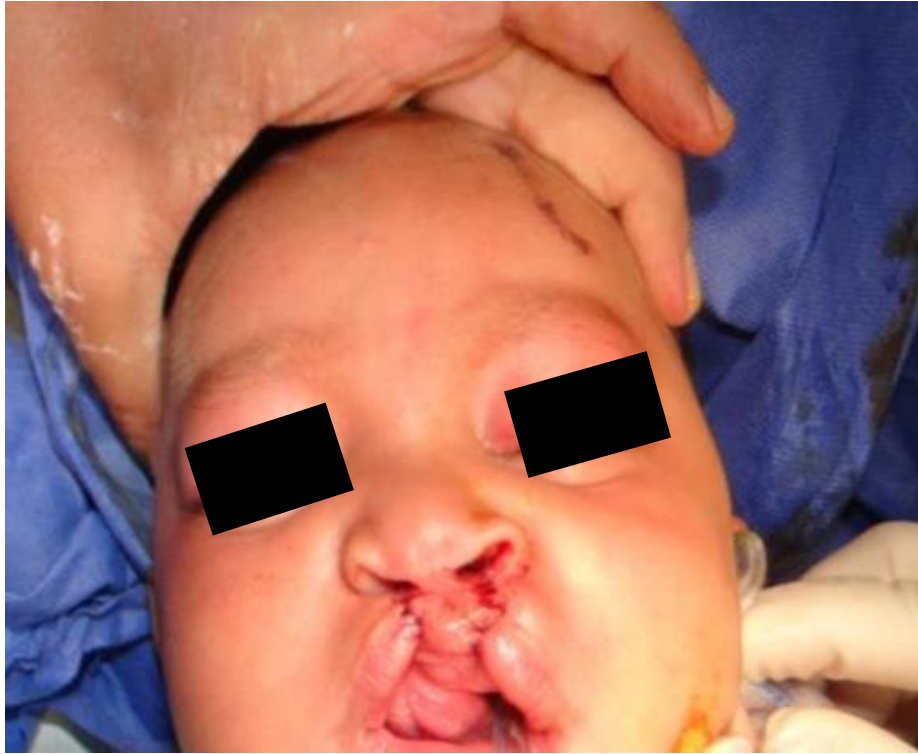


Figure (8): the second patient following the first stage.

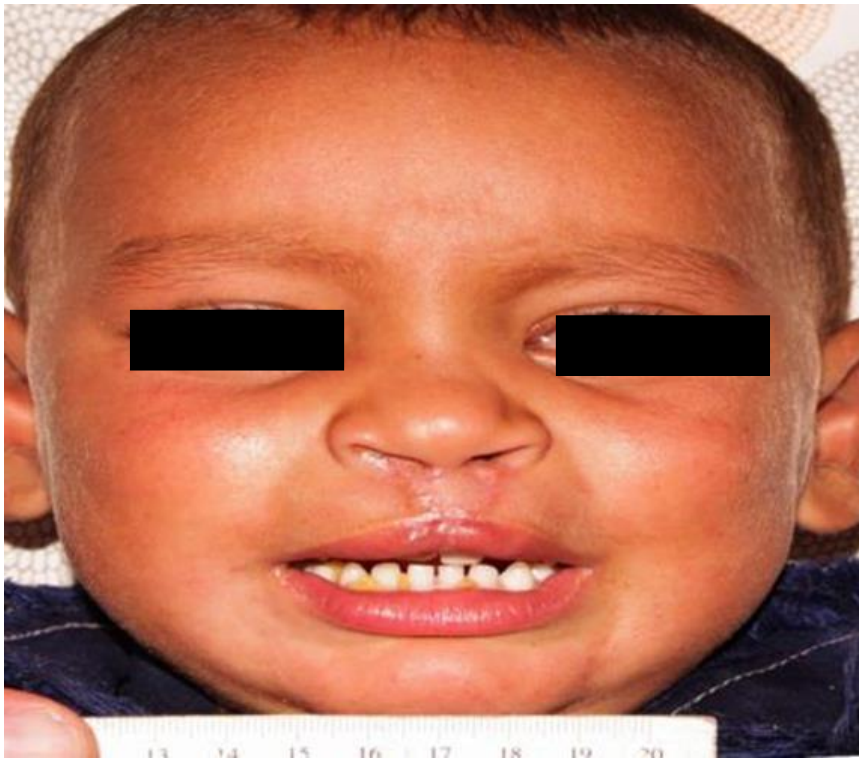

Figure (9): the second patient following the second stage.

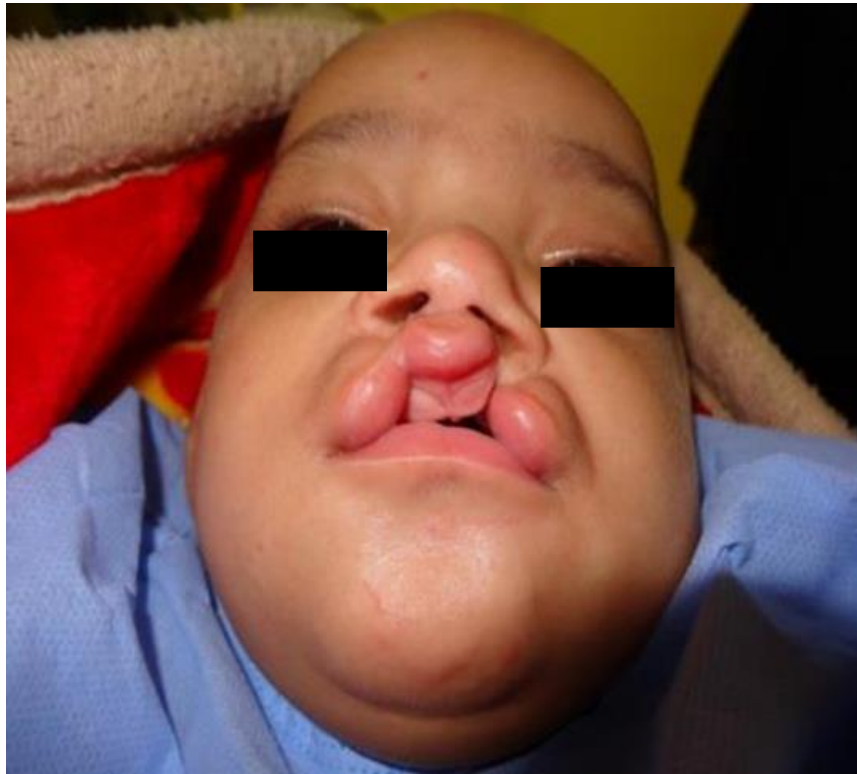

Figure (10): asymmetric cleft.

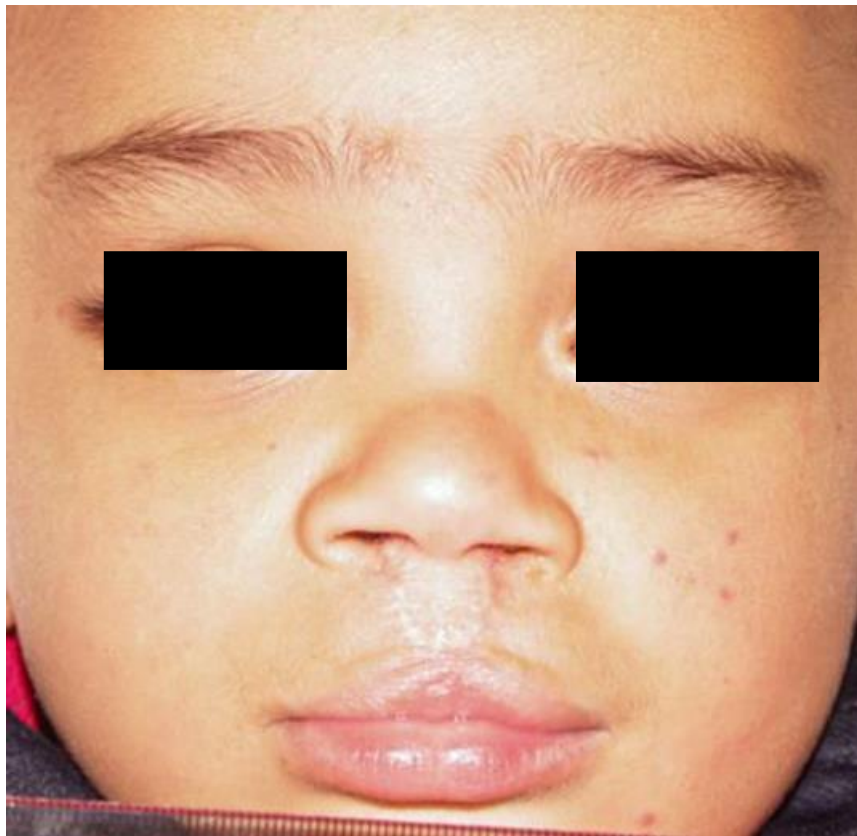

Figure (11): the same last patient 6 months after the second stage.

Discussion

Bilateral cleft lip repair remains very challenging and controversial. The results are not always satisfying for the surgeon and even the parents. Many surgical techniques were described and the ultimate aim was to achieve the best symmetry possible either by one staged techniques or multiple stages. (2)

The presurgical nasoalveolar molding is very beneficial in patients having bilateral cleft lip with protruded and rotated premaxilla. The nasoalveolar molding in these patients can correct the premaxilla protrusion or rotation if present and it reduces also the cleft gap. Nasoalveolar molding can help increasing the length of the columella.(17, 18)

We performed in our study nasoalveolar molding unless the patient was 3 months old or older than that because the nasoalveolar molding would not be effective at that advanced age. The 5 study patients that did not undergo nasoalveolar molding had symmetrical measurements. This point could then show that the staged repair was suitable for these cases in order to avoid the excessive tension on the muscles if one stage repair would be performed instead.(19)

Yuzuriha et al(12) reported in their study that they did staged repair for asymmetric cleft patients in the form of nasolabial adhesion on the wider side followed by delayed rotation advancement repair on this side associated with synchronous repair on the narrower side by rotation advancement with good results and more ability to achieve symmetry. The staged repair in our study helped us similarly to overcome the absence of a normal side template like in unilateral clefts by transforming every asymmetric bilateral cleft lip to a more symmetric form following the first stage. Xu et al(6) reported also that they did staged repair to all asymmetric bilateral cleft patients by starting by the wider side and then repairing the narrower side with good results. Similarly, Zhao et al(5) reported better results of staged repair compared to one stage in asymmetric bilateral clefts with discrepancy between both sides.

In our study we did a staged repair for displaced premaxilla patients and for patients having a prolabial height less than 6 mm. Xu et al(6) reported similar inclusion criteria for staged repair but they operated side by side and started by the wider-side.

Zhao et al(5) and Yuzuriha et al(12) reported as well better results after the staged repair in asymmetric clefts with considerable discrepancy between the 2 sides. They did a staged repair by operating the wider side first.

A recent systematic review by Chang et al(13) showed that many authors preferred the staged approach if the premaxilla was displaced more than 10 mm and in the absence of nasoalveolar molding to avoid any possible repair tension. In our study we did the staged repair for 3 patients with protruded premaxilla and

the protrusion improved after the nasoalveolar molding but the height of the prolabium in all of these patients was less than 6 mm. We did the staged repair as well for the 3 patients that had a rotated premaxilla to avoid any possible tension on the muscles after the repair.

Baek et al(10) had no acute complications after the one stage repair for bilateral cleft lip. Bezuhly et al(9) reported though in their study 4 post operative infections after the one stage repair including one major infection that required a redo. Similarly Keshk et al(20) reported 2 patients with wound dehiscence in their prospective study after the staged repair. In our study, the only patient that had a partial disruption after the first stage was that one with rotated premaxilla and no presurgical nasoalveolar molding and this could be explained by the excessive tension on the lip.

In our study, we performed photometrical analysis and antropometric measurements to evaluate the nasal width symmetry in both sides after the staged repair of bilateral clefts and we did not have any stastically significant difference between the right and left side measurements. Beak et al(10) reported in their retrospective review good symmetry outcome after using the same photometrical analysis technique to evaluate the nasal width symmetry after bilateral one stage cheiloplasty.

Similarly, Russell et al (21) reported in their retrospective study good symmetric measurements of the nose by using a computer software. In the latter study, they compared 15 patients of bilateral cleft lip to 15 age matched control patients.

On the contrary, Radwanska et al(22) reported in their retrospective study asymmetric measurements of nasal width in bilateral cleft lip but they used small calipers to measure manually .

We evaluated as well in our study the upper lip symmetry, horizontal lip length, alar symmetry and cupid's bow symmetry by a computer software photometrical analysis and we had symmetric measurements in our patients with no statistical significance between the right and left side in each patient. Beack et al(10) reported in their retrospective study symmetric measurements as well after using a similar photometrical analysis technique to assess the upper lip symmetry, horizontal lip length ,alar symmetry and cupid's bow symmetry after one stage bilateral cleft lip repair. On the other hand, Russell et al(21) reported in their study asymmetric outcomes after using a computer software for lip measurements when they compared bilateral cleft patients to age matched control patients. Interestingly, Aljancic et al(2) reported symmetric measurements in their retrospective study only for symmetric bilateral clefts and not for asymmetric clefts. In their study, they analysed objectively the patients photographs after one stage modified Millard's technique.(23) In our study, we had

symmetric measurements by photometric analysis for symmetric and asymmetric cleft patients.

The main limitations of the current study are the small number of patients included in the study and the absence of comparison between the described staged repair and other types of staged repair and between the described staged repair and the single stage repair for bilateral cleft lip.

Conclusion

The staged repair in bilateral cleft lip as described in the current study is safe and leads to upper lip symmetry. A further prospective study with a larger number of patients preferably comparing one stage versus the described staged repair and comparing between the different techniques of staged repair of bilateral cleft lip to achieve consensus regarding the better option for each patients category is necessary.

Fund

No fund was received from any funding agency

Conflict of interest

No conflict of interest

Ethics committee reference number

IRB NO:00012098 (expires 2025) – FWA NO:00018699 (expires 21/1/2026)

Serial number of the study:0201464

References

1. Liau JY, van Aalst JA, Sadove AM. Understanding and caring for children with cleft lip and palate. In: Coran AG, Caldamone A, Adzick NS, Krummel TM, Laberge JM, Shamberger R, (eds). Pediatric surgery. USA: Elsevier Health Sciences; 2012. 699-706.
2. Aljancic L, Rougier G, Neiva-vaz C, Vazquez M-P, Picard A, Kadlub N. Millard's modified technique in the reconstruction of bilateral cleft lip: Objective and subjective assessment. J Stomatol Oral Maxillofac Surg. 2022;123(5):532-7.

3. Gkantidis N, Papamanou DA, Karamolegkou M, Dorotheou D. Esthetic, functional, and everyday life assessment of individuals with cleft lip and/or palate. *Biomed Res Int.* 2015;2015:510395.
4. Iliopoulos C, Mitsimponas K, Lazaridou D, Neukam FW, Stelzle F. A retrospective evaluation of the aesthetics of the nasolabial complex after unilateral cleft lip repair using the Tennison-Randall technique: a study of 44 cases treated in a single cleft center. *J Craniomaxillofac Surg.* 2014;42(8):1679-83.
5. Zhao X, Wu Y, Wang G, Yang Y, Cai M. Repair of Asymmetric Bilateral Cleft lip: 1 Stage or 2 Stage. *Cleft Palate Craniofac J.* 2022;59(4):436-41.
6. Xu H, Salyer KE, Genecov ER. Primary bilateral one-stage cleft lip/nose repair: 40-year Dallas experience: part I. *J Craniofac Surg.* 2009;20 Suppl 2:1913-26.
7. Aburezq H, Daskalogiannakis J, Forrest C. Management of the prominent premaxilla in bilateral cleft lip and palate. *Cleft Palate Craniofac J.* 2006;43(1):92-5.
8. Chung KH, Lo LJ. One-stage versus two-stage repair of asymmetric bilateral cleft lip: A 20-year retrospective study of clinical outcome. *Plast Reconstr Surg.* 2018;141(5):1215-24.
9. Bezuhly M, Fisher DM. Single-stage repair of asymmetrical bilateral cleft lip with contralateral lesser form defects. *Plast Reconstr Surg.* 2012;129(3):751-7.
10. Baek RM, Myung Y, Park I, et al. A new all-purpose bilateral cleft lip repair: Bilateral cheiloplasty suitable for most conditions. *J Plast Reconstr Aesthet Surg.* 2018;71(4):537-45.
11. Xu H, Salyer KE, Genecov ER. Primary bilateral two-stage cleft lip/nose repair: part II. *J Craniofac Surg.* 2009;20 Suppl 2:1927-33.
12. Yuzuriha S, Oh AK, Mulliken JB. Asymmetrical bilateral cleft lip: complete or incomplete and contralateral lesser defect (minor-form, microform, or mini-microform). *Plast Reconstr Surg.* 2008;122(5):1494-504.
13. Chang IA, Bassiri Gharb B, Papay FA, Rampazzo A. Repair Sequence and management of the premaxilla in patients with bilateral cleft lip and palate: A systematic review of the literature. *J Craniofac Surg.* 2022;33(2):421-5.
14. Tse R. Unilateral cleft lip: principles and practice of surgical management. *Semin Plast Surg.* 2012;26(4):145-55.
15. Kohout MP, Aljaro LM, Farkas LG, Mulliken JB. Photogrammetric comparison of two methods for synchronous repair of bilateral cleft lip and nasal deformity. *Plast Reconstr Surg.* 1998;102(5):1339-49.
16. Kim SK, Kim MH, Kwon YS, Lee KC. Long-term results in the bilateral cleft lip repair by Mulliken's method. *J Craniofac Surg.* 2009;20(5):1455-61.

17. Grill FD, Rau A, Bauer FX, et al. The absolute and relative effects of presurgical nasoalveolar moulding in bilateral cleft lip and palate patients compared with nasal growth in healthy newborns. *J Craniomaxillofac Surg.* 2019;47(7):1083-91.
18. El-Ashmawi NA, Fayed MMS, El-Beialy A, Attia KH. Evaluation of the clinical effectiveness of nasoalveolar molding (NAM) using grayson method versus computer-aided design NAM (CAD/NAM) in infants with bilateral cleft lip and palate: A randomized clinical trial. *Cleft Palate Craniofac J.* 2022;59(3):377-89.
19. Manosudprasit M, Wangsrimongkol T, Pisek P, Wiwatworakul O. Pre-surgical nasoalveolar molding technique: a literature review. *J Med Assoc Thai.* 2014;97 Suppl 10:S17-24.
20. Keshk TF, Omar AA, Elsaka DM, Elsheikh YM, AboShaban MS. Different modalities for the management of bilateral cleft lip. *Menoufia Med J.* 2015;28(1):107-13.
21. Russell JH, Kiddy HC, Mercer NS. The use of SymNose for quantitative assessment of lip symmetry following repair of complete bilateral cleft lip and palate. *J Craniomaxillofac Surg.* 2014;42(5):454-9.
22. Radwańska K, Radwański M, Antoszewski B. The assessment of facial asymmetry in patients with uni- or bilateral cleft lip and palate. *Pomeranian J Life Sci.* 2021;67(2):6-9.
23. Byrd HS, Ha RY, Khosla RK, Gosman AA. Bilateral cleft lip and nasal repair. *Plast Reconstr Surg.* 2008;122(4):1181-90.